

Case Report of Foveolitis with Optic Neuritis: A Barely encountered Ophthalmic Manifestation of Dengue

Bipin Bista, Ranju Kharel Sitaula, Dichen M Lama, Sanjeeta Sitaula

Author(s) affiliation

Department of Ophthalmology,
Maharajgunj Medical Campus, BP
Koirala Lions Centre for Ophthalmic
Studies, Institute of Medicine,
Maharajgunj, Kathmandu, Nepal

Corresponding author

Ranju Kharel Sitaula, MD, FAICO
hellorranju50@gmail.com

ABSTRACT

Dengue fever is a tropical disease which is endemic in tropical/subtropical nations like Nepal. Bilateral optic neuritis with unilateral foveolitis is an unusual dengue-related ophthalmic complication. We here present to you a case of bilateral optic neuritis with right eye foveolitis who initially presented with complaints of sudden diminution of vision in one eye following dengue fever. This report deals with prolonged treatment of rare ocular presentation of dengue infection. Patient had persistent myodesopsia and scotoma in the right eye even after 5 months of treatment with oral steroids. Dengue-related ophthalmic findings although rare, can have significant and long-lasting visual impairment if not treated timely and appropriately.

Keywords

Dengue; foveolitis; optic neuritis

Submitted

Aug 27, 2023

Accepted

Sep 20, 2023

INTRODUCTION

Dengue has been a significant public health problem in tropical countries and is troublesome and burden for developing countries like Nepal. Dengue fever is a neglected tropical disease (NTD) caused by dengue virus (DENV) serotypes DENV1, DENV2, DENV3 and DENV4 viruses.¹

It is transmitted to humans mainly by the *Aedes aegypti* and *Aedes albopictus*. Most of the dengue fevers are self-limited and are characterized by fever, headache, retro-orbital pain, loss of appetite and vomiting.² Very few dengue related ophthalmic cases has been reported.³⁻⁴

This case features unusual ophthalmic findings which presented a week after dengue infection with bilateral optic neuritis and right eye foveolitis.

CASE PRESENTATION

A 37-year-old male from Kathmandu presented to the outpatient department with the complaint of sudden, painless loss of vision since 2 days associated with black spots and curtain-like visual obscurations in the right eye. It was preceded by increased body temperature (~103°F) and severe back pain and the patient had tested positive for dengue a couple of days ago. The patient did not have any other co-morbidities. On detailed ophthalmic examination, his best corrected vision was noted as 20/200, N10 in the right eye and 20/20, N6 in the left eye. Slit lamp evaluation unveiled quiet anterior segment findings in both the eyes but the posterior segment examination showed blurred disc margin with mild edema and hyperemia along with splinter hemorrhage in all four quadrants suggestive of disc edema in both the eyes. Dull foveal reflex was also seen in the right eye. Farnsworth Munsell color test showed toward tritan defect in right eye. Optical coherence tomography depicted minimal RPE changes with hemorrhage over Nerve Fiber Layer defect in right eye. (Figure 1).

After clearance from internist and infectious department, the patient was started with oral steroid with 60 mg per kg per oral for a week and was tapered gradually in 5 days interval. After initiation of steroid, though the patient had persistent myodesopsia, there was quick improvement in visual acuity as well as resolution of disc oedema and splinter hemorrhages. However, the patient gradually developed central serous chorioretinopathy from the second week of treatment for which he was prescribed with topical NSAIDs. In second follow up, two weeks after cessation of steroid therapy, there was increased sub-retinal fluid in the macular area and intraretinal edema with disruption of IS-OS junction with hyper-reflective fragments of exudates suggestive of foveolitis with serous detachment in right eye. Patient was again started with low dose steroid in rapid tapering dose manner along with

topical NSAIDs. (Figure 2).

After 3 months follow-up, the patient's vision improved from 20/200 to 20/80 but his myodesopsia persisted. Right eye fundus examination showed resolution of sub-retinal fluid but fovea still showed dull reflex (Figure 3). There was disruption of ellipsoid zone along with Internal Limiting Membrane (ILM) layer which was still evident while disc edema and macular edema had subsided completely. (Figure 4).

DISCUSSION

The exact cause for ocular involvement in dengue is not known. There are multiple suggested hypotheses like low platelet count leading to bleeding, leakage due to increased permeability by pro-inflammatory cytokines added to coexistent inflammation or an immune mediated hypothesis.^{3,4} The three patterns of maculopathy that have been described on OCT are foveolitis, diffuse retinal thickening and cystoid macular edema.⁵ Ocular symptoms include blurring of vision, with other symptoms like ocular pain, redness, metamorphopsia, impaired color vision, diplopia, flashes and floaters, haloes, and photophobia.⁵⁻⁷

Observed signs on examination are reduced visual acuity, scotomas, sub-conjunctival or retinal hemorrhage, anterior uveitis, focal or pan retinal vasculitis, inflammatory maculopathy with chorioretinitis. Other signs being exudative retinal detachment, perifoveal telangiectasia, cotton wool spots, optic disc swelling and hyperemia.^{3,8,9,10} Incidence of foveolitis in patients with maculopathy were 28.0 to 33.7%.^{5,10} Apart from fundoscopic evaluation, OCT also plays important role in assessment of morphology and thickness of retinal structure. Prognosis is variable with better visual outcome in diffuse edema but persisting scotoma may remain for longer period in cases of foveolitis.

Definitive management is still argumentative.

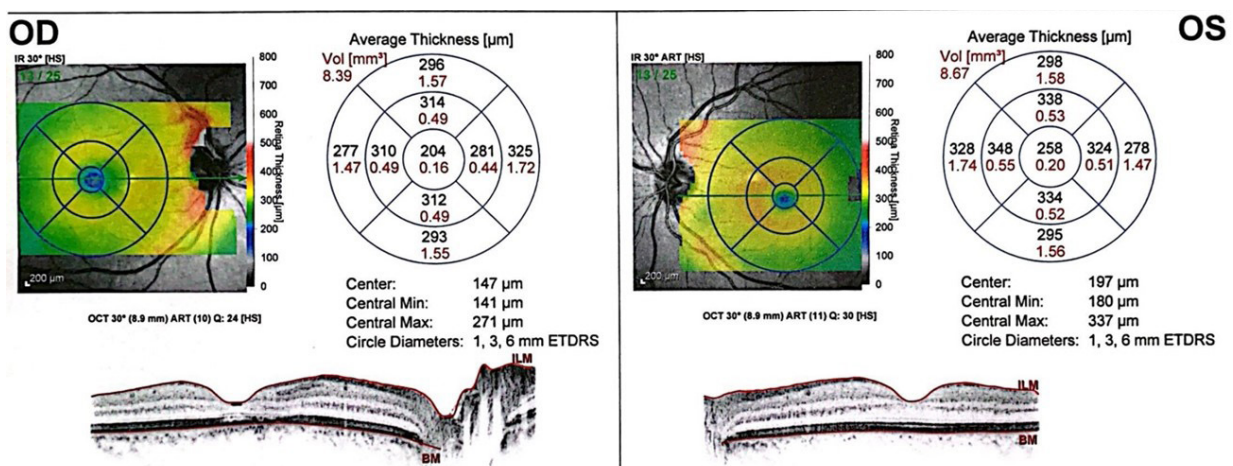


Figure 1. Right eye OCT showing the presence of RPE changes with hemorrhage over nerve fiber layer

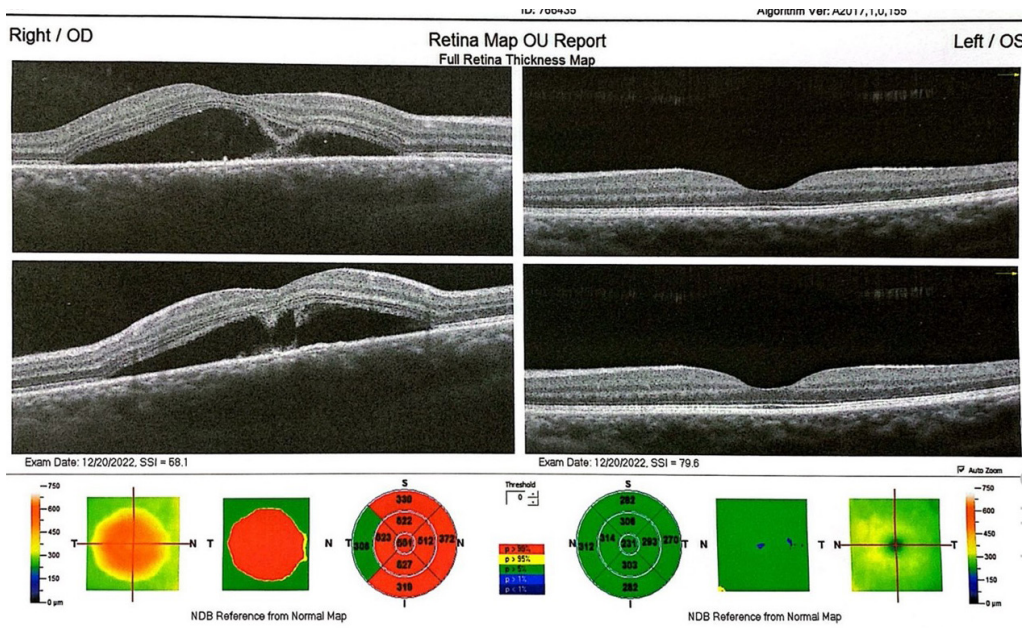


Figure 2. Marked subretinal fluid with exudates with disrupted ellipsoid zone suggestive of foveolitis

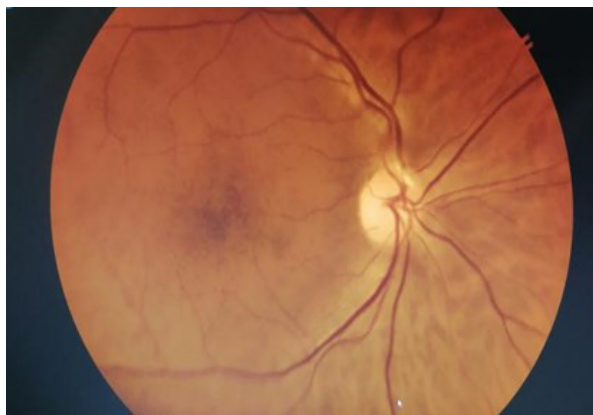


Figure 3. Right eye fundus picture showing resolution of serous RD and persistence of dull foveal reflex at the site of foveolitis

Treatment modality can be from close observation and follow up, or glucocorticoid therapy which can be topical, oral, Intravitreal or sub-tenon triamcinolone injection.^{4,8} Intravenous immunoglobulin has shown to be beneficial in cases with failed steroid response.⁷ Our patient was managed initially with passive treatment. Later on, the patient was given oral steroid in tapering dose. The patient had gradual improvement in visual acuity but the complaint of scotoma and floaters persisted for a long period of 6 months.

CONCLUSION

With increased incidence of dengue infection in Nepal, it is a matter of prime importance to look after ophthalmic manifestation of this disease as

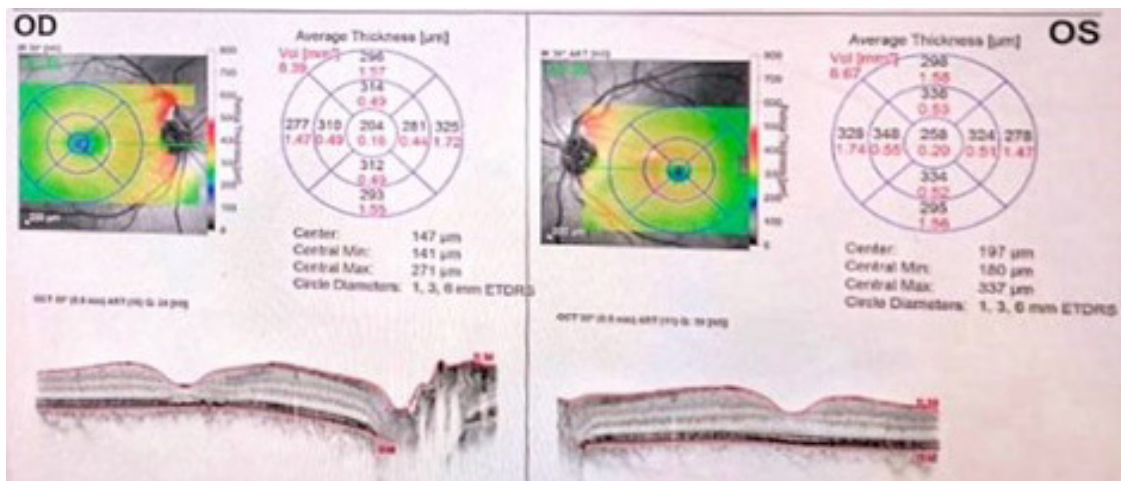


Figure 4. Resolution of the sub-retinal fluid with persisting ellipsoid zone and internal limiting membrane disruption

well. Ocular involvement though rare, can have a variable degrees of ophthalmic complications and can even be sight threatening if not appreciated in right time.

Further, crisp investigation and detailed ophthalmic evaluation is a necessity to address these ophthalmic sequelae post dengue infection in countries like Nepal where the incidence of Dengue infection is going through an exponential increment.

CONSENT

The written informed consent was taken from the patient regarding the case report publication.

FINANCIAL SUPPORT

The author(s) did not receive any financial support for the research and/or publication of this article.

CONFLICT OF INTEREST

The author(s) declare that they do not have any conflicts of interest with respect to the research, authorship, and/or publication of this article.

REFERENCES

1. Phuyal P, Kramer IM, Kuch U, Magdeburg A, Groneberg DA, Lamichhane Dhimal M, Montag D, Harapan H, Wouters E, Jha AK, Dhimal M. The knowledge, attitude and practice of community people on dengue fever in Central Nepal: a cross-sectional study. *BMC Infectious Diseases*. 2022 Dec;22(1):1-8.
2. Thant Z, Tengku MA, Azmi H, Norizhar K. Dengue Virus Infections: Global Scenario, Classification, and Clinical Manifestations—A Review. *Research Journal of Pharmacy and Technology*. 2016;9(1):83-90.
3. Teoh SC, Chan DP, Laude A, Chee C, Lim TH, Goh KY. Dengue chorioretinitis and dengue-related ophthalmic complications. *Ocul Immunol Uveitis Found*. 2006;9(4):1-9.
4. Gupta A, Srinivasan R, Setia S, Soundravally R, Pandian DG. Uveitis following dengue fever. *Eye*. 2009 Apr;23(4):873-6.
5. Teoh SC, Chee CK, Laude A, Goh KY, Barkham T, Ang BS, Eye Institute Dengue-related Ophthalmic Complications Workgroup. Optical coherence tomography patterns as predictors of visual outcome in dengue-related maculopathy. *Retina*. 2010 Mar 1;30(3):390-8.
6. Lim WK, Mathur R, Koh A, Yeoh R, Chee SP. Ocular manifestations of dengue fever. *Ophthalmology*. 2004 Nov 1;111(11):2057-64.
7. Yip VC, Sanjay S, Koh YT. Ophthalmic complications of dengue fever: a systematic review. *Ophthalmology and therapy*. 2012 Dec;1:1-9.
8. Chan DP, Teoh SC, Tan CS, Nah GK, Rajagopalan R, Prabhakaragupta MK, Chee CK, Lim TH, Goh KY, Eye Institute Dengue-Related Ophthalmic Complications Workgroup. Ophthalmic complications of dengue. *Emerging infectious diseases*. 2006 Feb;12(2):285.
9. Tan CS, Teoh SC, Chan DP, Wong IB, Lim TH. Dengue retinopathy manifesting with bilateral vasculitis and macular oedema. *Eye*. 2007 Jun;21(6):875-7.
10. Loh BK, Bacsal K, Chee SP, Cheng BC, Wong D. Foveolitis associated with dengue fever: a case series. *Ophthalmologica*. 2008;222(5):317-20.