

Pyogenic Granuloma of External Auditory Canal: A Case Report

Utsav R Karki¹, Kripa Dongol¹, Rabindra B Pradhananga¹, Bikash K Shah²

Author(s) affiliation

¹Department of Otorhinolaryngology and Head and Neck Surgery, Maharajgunj Medical Campus, Tribhuvan University Teaching Hospital, Institute of Medicine, Maharajgunj, Kathmandu, Nepal

²Maharajgunj Medical Campus, Institute of Medicine, Maharajgunj, Kathmandu, Nepal

Corresponding author

Utsav R Karki, MBBS
utsavrajkarki83@gmail.com

ABSTRACT

The external auditory canal is an atypical location for pyogenic granuloma (PG) to originate. We report a case of PG in a 15-year-old boy's external auditory canal. He experienced reduced hearing and occasional blood-tinged ear discharge for 8 months. Examination revealed a pinkish-soft mass occluding the canal lumen. Pure tone audiogram showed 42 dB moderate conductive hearing loss in the right ear. High-resolution computed tomography showed a well-defined, homogenously enhancing soft tissue density lesion in the canal. The mass was completely excised, and post-operative histopathology confirmed the diagnosis of PG. No recurrence was observed during the six-month follow-up period. PG should be considered in the differential diagnosis of external auditory canal lesions.

Keywords

External auditory canal, lobular capillary hemangioma, pyogenic granuloma

INTRODUCTION

Pyogenic granuloma (PG), also known as lobular capillary hemangioma (LCH) is an acquired benign vascular tumor of skin and mucous membrane. PG is neither a pyogenic infection nor granulomatous inflammation.¹⁻³ The exact etiology is still unclear, however, it is proposed to arise from chronic irritation, traumatic injuries, female sex hormones or a background of immunosuppression.^{1,3,4} The current International Society for the Study of Vascular Anomalies (ISSVA) classifies vascular anomalies into 2 main categories, namely vascular tumors and vascular malformations. Vascular tumors are further divided into benign, locally aggressive and malignant tumors. PG belongs to a benign vascular tumor.⁵

PG may involve any gender and age, but it is more common in females in the second and third decades of life.^{6,7} There is increased preponderance during pregnancy and women under oral hormonal therapy.^{2,8} The most common site of occurrence is the head and neck area, especially the

Submitted

Sep 13, 2023

Accepted

Nov 20, 2023

oral cavity and nasal mucosa, followed by the upper limbs, trunk and lower limbs. Although the head and neck areas are the most common site, it rarely occurs in the external auditory canal (EAC).^{2,4,6} Only a few cases of EAC pyogenic granulomas have been documented in the literature to our knowledge. Here we present a case of a 15-year-old boy with PG of the external auditory canal and review the relevant literature.

CASE PRESENTATION

A 15 year male presented to our clinic with complaints of right-sided decreased hearing associated with aural fullness and intermittent blood-tinged right ear discharge for 8 months. He also noticed a pinkish mass in his right ear canal for 2 months. He had no history of trauma to the ear, earache, pulsatile tinnitus, vertigo or facial asymmetry. He denied a history of ear picking or any systemic illnesses. On examination, the cartilaginous portion of the right EAC lumen was completely occluded by a pinkish, soft mass with regular margin, whereas the left ear was normal. Rinne test was negative on the right ear, and positive on the left ear and Weber was lateralized to the right ear performed using a 512 Hz tuning fork.

A pure tone audiogram revealed 42 dB moderate conductive hearing loss in the right ear. The hearing was within normal limit on the left ear. High-resolution computed tomography (HRCT) temporal bone revealed a well-defined soft tissue density lesion noted in the right EAC measuring 17x10 mm in size with the presence of calcification, post-contrast study showed intense homogenous enhancement and no erosion of scutum or surrounding the bony structure. (Figure 1a and 1b)

The case was planned for excision of the mass. Post-aural incision was given and another incision was given permealately using a round knife in bony EAC under general anesthesia. Tumor mass peeled from EAC skin and the bony EAC wall was drilled. Surgical excision with base cauterization using bipolar cautery was performed, with excision of ~1.0 x 1.0 cm sized mass attached to antero-superior wall of EAC approximately 3 mm lateral to the tympanic membrane (Figure 2a and 2b). Histopathological examination of surgically excised specimen showed multiple polypoidal tissues lined by stratified squamous epithelium, subepithelium showed multiple interconnected proliferating capillaries in lobules with mild lymphoplasmacytic infiltration along with neutrophils suggesting lobular capillary hemangioma, negative for malignancy (Figure 3). There was no evidence of recurrence until 6 months of follow-up postoperatively.

DISCUSSION

Pyogenic granuloma is newly known as lobular capillary hemangioma as its histopathological examination reveals circumscribed capillaries arranged in lobules that are separated by fibrous bands.¹⁴ EAC is a very uncommon location for PG. There are a few reported cases of multiple PG of EAC and a few reported cases of bilateral PG.^{3,6} It is more common in females in the second and third decades. Mills et al. reported that patients younger than 18 years of age were predominantly males (82%), whereas those between the ages of 18 and 39 years were predominantly females (86%).² Our patient was a 15-year-old boy with no history of otological trauma, irritation of EAC or immune disorder.

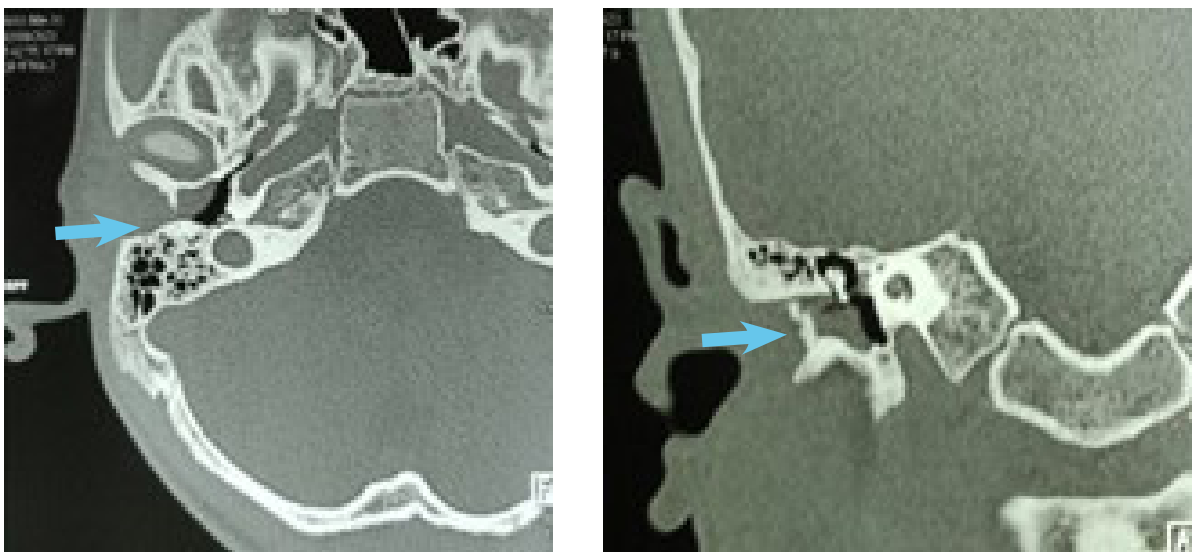


Figure 1a & 1b. Axial and coronal films of HRCT temporal bone showing soft tissue density in Right External Auditory Canal (blue arrow)

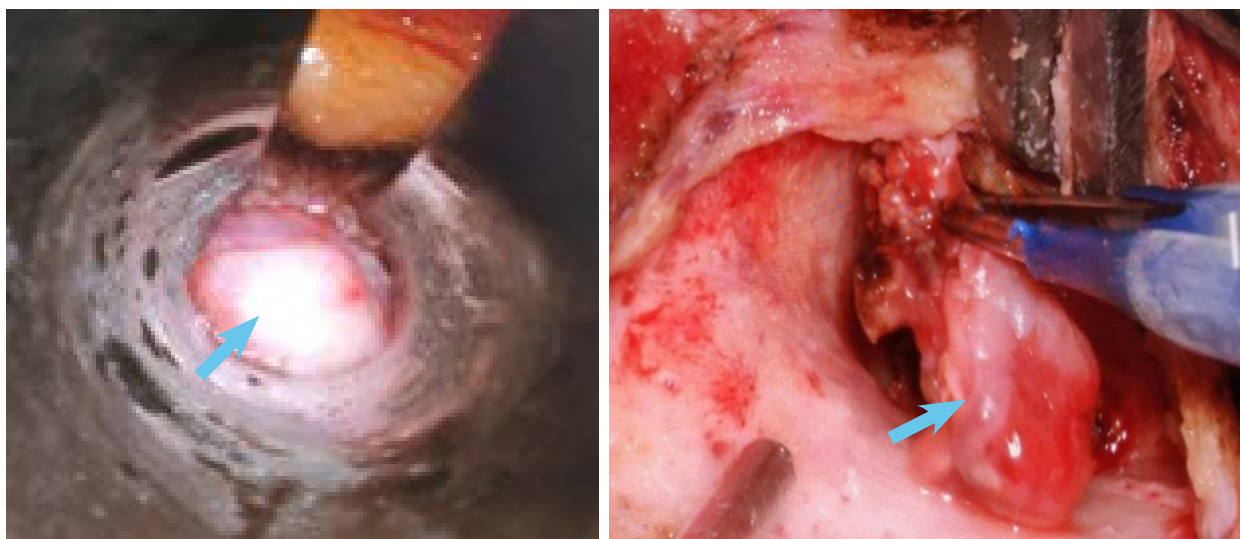


Figure 2a & 2b. Pinkish smooth mass (blue arrow) arising from bony EAC and post-excision specimen (blue arrow)

External auditory canal pyogenic granuloma may be asymptomatic or may present with variable symptoms like aural fullness, recurrent blood-tinged otorrhea, otalgia, pulsatile tinnitus, conductive hearing loss or red-purple mass.⁴ In our case, the patient had right-sided 42 dB moderate conductive hearing loss along with aural fullness and recurrent blood-tinged otorrhea. Possible differentials include attic cholesteatoma with aural polyp, granulations, paragangliomas, EAC hemangiomas, aberrant carotid artery, high jugular bulb and carcinoma.^{4,9}

High-resolution computed tomography (HRCT) scan of temporal bone, magnetic resonance imaging (MRI) and angiography are preferred modalities of investigations if EAC PG or hemangioma is suspected. HRCT temporal bone is primarily performed as it helps in determining the extent of lesions, middle ear extension and bony erosion. MRI additionally helps to identify vascular tumor from malignancy. An angiogram is not usually needed but may be helpful in the identification and embolization of the feeding vessel if the lesion is advanced and excessive bleeding is expected.^{1,4,6,8,10} But for the definitive diagnosis, a final histopathological examination is needed after the excision of the lesion.^{1,4,9,10}

The preferred choice of treatment is a complete surgical excision via transcanal or postaural approach with the lowest recurrence rate. As per Andaloro et al., the recurrence rate after surgical excision is 2.94 %.¹ Other modalities include cryosurgery, curettage followed by electrocautery, laser ablation, and embolization or sclerosing agents. Kirschner et al. reported the recurrence rate following laser (argon and KTP) to be 4.8 %.²

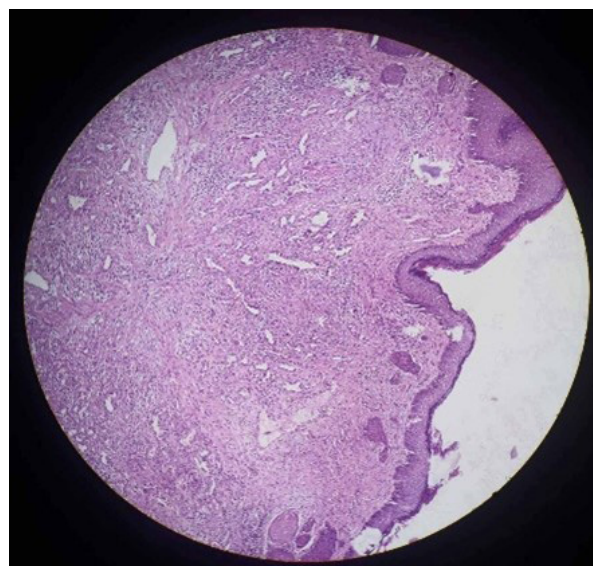


Figure 3. Histopathological photograph of lobular capillary hemangioma (H&E stain, 40x magnification) showing proliferating capillaries in lobules

Akamatsu et al. recommend surgical excision followed by CO₂ laser ablation as the first choice as there is less pain and recurrence following CO₂ laser ablation (0%).¹ Incomplete excision and failure to avoid etiological factors & re-injury to the same area are the factors causing recurrence.² However, in our case, complete surgical excision via post-aural approach was performed along with electrocauterization of the base using bipolar cautery, with no evidence of recurrence until 6 months of follow-up postoperatively.

CONCLUSION

Pyogenic granuloma of EAC is a rare condition but should be considered in the differential diagnosis of EAC lesions. Pure tone audiogram, HRCT temporal bone and final histopathological examination are essential for its diagnosis. Surgical excision still remains the choice of treatment with a very low recurrence rate. However, subsequent follow-up is advised to find out possible recurrence.

CONSENT

The written informed consent was taken from the patient's guardian regarding the case publication.

ACKNOWLEDGEMENT

The authors acknowledge the help and support received from the Department of Otorhinolaryngology Head and Neck Surgery and Pathology, Tribhuvan University Teaching Hospital.

FINANCIAL SUPPORT

The author(s) did not receive any financial support for the research and/or publication of this article.

CONFLICT OF INTEREST

The author(s) declare that they do not have any

conflicts of interest with respect to the research, authorship, and/or publication of this article.

REFERENCES

1. Andaloro C, Corsitto R, Florio F, et al. Giant pyogenic granuloma of the external auditory canal: A rare case report. *B-ENT* 2022;18(2):131-134.
2. Akamatsu T, Hanai U, Kobayashi M, Miyasaka M. Pyogenic granuloma: a retrospective 10-year analysis of 82 cases. *Tokai J Exp Clin Med*. 2015 Sep 20;40(3):110-4.
3. Hsu CH, Chen HC, Wang CH. Bilateral external auditory canal pyogenic granuloma. *Otolaryngology-Head and Neck Surgery*. 2008 Oct 1;139(4):596-7.
4. Topdag M, Mutlu A, Sari F, Ozturk M. An external auditory canal lesion: lobular capillary hemangioma. *J Otolaryngol ENT Res*. 2014;1(1):00005.
5. Dasgupta R, Fishman SJ. ISSVA classification. In *Seminars in pediatric surgery* 2014 Aug 1 (Vol. 23, No. 4, pp. 158-161). WB Saunders.
6. Lee HJ, Kim JY, Lee JM. Multiple Pyogenic Granulomas in the External Auditory Canal. *Ear, Nose & Throat Journal*. 2022 Nov 25:01455613221142734.
7. Kurtaran H, Uraldi C, Ark N, Aktaş D. Lobular capillary haemangioma of the middle turbinate. *Acta oto-laryngologica*. 2006 Jan 1;126(4):442-4.
8. Dick DC, Elliott K, Napier S, Adair R. Pregnancy tumour of the external auditory canal: treatment in clinic. *Case Reports*. 2016 Feb 16;2016:bcr2015213673.
9. Rutherford KD, Leonard G. Hemangiomas of the external auditory canal. *American journal of otolaryngology*. 2010 Sep 1;31(5):384-